

DIAGNOSIS AND MANAGEMENT ISSUES IN NF 1 & NF 2 AND OTHER GENETIC BRAIN TUMORS





INTRODUCTION

- The neurofibromatosis (NF) is a heterogeneous group of disorders characterized by abnormal skin pigmentation and numerous neuroectodermal tumors.
- Several types of NF are described, two distinct forms usually covers most. These two forms share some similarities but are distinct entities caused by genes on different chromosomes .

- Phakomatosis (greek root phakos=birthmark) are a group of hereditary disorders with cutaneous, ocular and neurological manifestation; these include neurofibromatosis, tuberous sclerosis complex, von Hippel-Lindau disease and the neurocutaneous angiomas.
- The variable expression and overlap of many of these disorders can make diagnosis difficult. Evaluations of multiple systems and multiple family members is best accomplished by a multidisciplinary group, including geneticist, ophthalmologist, dermatologist, neurologist and neurosurgeon. Diagnosis and treatment should be designed for the affected patient and his family members in a way to avoid fragmentation of medical care.



HISTORICAL PERSPECTIVE

- Sporadic description of multiple dermal tumors “*wart man*”, and a likely diagnosis of NF1, appeared in 17th & 18th centuries (Monstrorum historia 1642).
- In 1849, Robert Smith from Dublin medical school reported the clinical and autopsy finding of two cases of NF .
- Friedrich Daniel von Recklinghausen, a student of Virchow, in 1882 credited with the first thorough description of NF .
- Marie, Bernard and Chauffard (1896) described the significance of *café-au-lait spots*. Lisch (1937) drew attention of pigmented iris nodules and Crowie (1964) described axillary frecklings.
- Term phakomatosis coined by van der Hoeve in 1920.

- Thomson in 1900 described familial basis of the disorder. Preiser and Davenport (1918) described autosomal dominant inheritance of the condition.
- Ricardi (1982) followed by Evans (1992) described about NF2 .
- Based on the public attention & interest on NF1 from the movie ‘the elephant man’ , National Neuro-Fibromatosis Foundation (NNFF) conceptualized and setup.
- In 1987, diagnostic criteria were laid down for NF1 & NF2 by National Institutes of Health Consensus development conference .

GENETIC AND CLINICAL FEATURES OF PHAKOMATOSIS

DISORDER	GENETICS	NEUROLOGICAL FEATURE	GENERAL FEATURES
Neurofibromatosis-1	Autosomal dominant (17q)	Spinal NF, plexiform NF, Optic glioma, cerebral and posterior fossa glioma, macrocephaly, hydrocephalus, scoliosis, cranial and vertebral dysplasia, learning disorders and seizures.	Skin neurofibromas, café au lait spots, intertriginous freckles, iris hamartoma, pheochromocytoma, hemihypertrophy, neurofibrosarcoma.
Neurofibromatosis-2	Autosomal dominant (22q)	Bilateral acoustic schwannoma, meningioma, spinal schwannoma, ependymoma, astrocytoma	Posterior subcapsular cataract.
Tuberous sclerosis complex	Autosomal dominant (9q, 11q, 12q, 14)	Subependymal nodules & giant cell astrocytoma, cortical tubers, seizures, mental retardation.	Ash-leaf spot, shagreen patches, adenoma sebaceum, subungual fibromas, tooth pitting, cardiac rhabdomyoma.
Von Hippel-Lindau disease	Autosomal dominant (3p)	Hemangioblastoma of the cerebellum, spinal cord or brain stem.	Retinal hemangioblastoma, renal cyst/carcinoma, pheochromocytoma

GENETIC AND CLINICAL FEATURES OF PHAKOMATOSIS

Ataxia-telangiectasia	Autosomal dominant (11q)	Ataxia, dysarthria, choreo-athetosis, polyneuropathy, cerebellar & spinal degeneration, intellectual impairment	Telangiectasia, leukemia, lymphoma, Ca breast, radiation hypersensitivity, immunodeficiency
Sturge-Weber syndrome	Somatic mutation	Parieto-occipital angioma, seizures	Hemangioma of retina, facial angioma
Klippel-Trenaunay-Weber syndrome	Somatic mutation	Spinal angioma.	Dermatomal hemangioma.
Rendu-Osler-Weber syndrome	Autosomal dominant	CNS angioma and hemorrhage	Epistaxis, gastric hemorrhage.
Wyburn-Mason syndrome	Uncertain	AVM of midbrain, mental changes.	Facial nevi
Fabry's disease	X-linked recessive	Painful polyneuropathy, stroke.	Telangiectasia of leg & abdomen, renal failure, hypertension, MI.



GENETIC PATHOGENESIS

NF1:

- Neurofibromatosis-1 gene is inherited in autosomal dominant pattern with high penetrance but variable and unpredictable expression.
- Prevalence – 1:4000 live births, 50% with +ve family history.
- Gene responsible is located in pericentric region of chromosome 17(long arm).
- NF1 gene is a tumor-suppressor gene. Neurofibromin, a NF1 gene product, interact with *ras* p21 oncogene to produce an inactive state and limits cell growth. A mutated neurofibromin molecule could not control cell growth thereby resulting in accelerated cell proliferation.

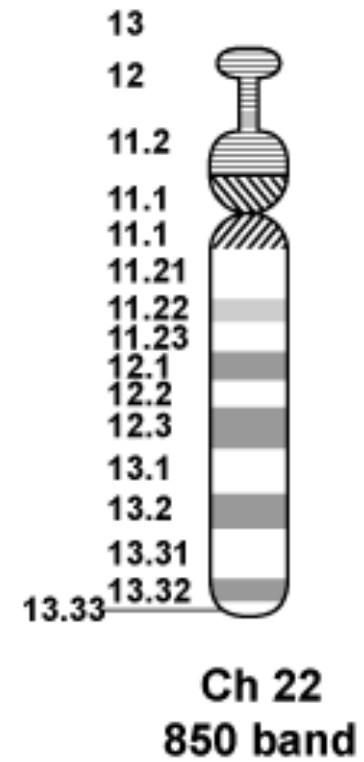
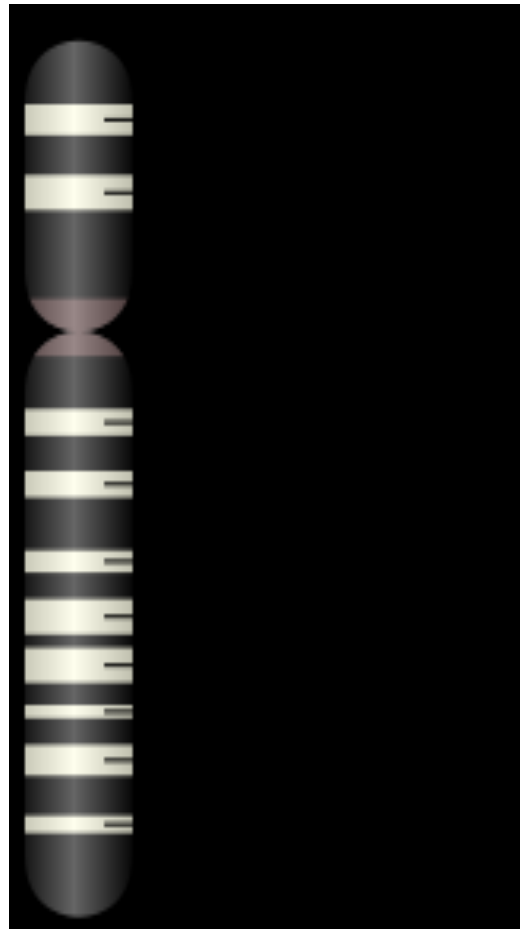


GENETIC PATHOGENESIS

NF2:

- Inherited in autosomal dominant pattern
- Incidence of the disease is about 1 in 40,000. 50% are inherited & rest due to de novo mutations.
- Defect in the gene that normally gives rise to a product called Merlin or Schwannomin, located on chromosome 22 band q11-13.1 which have tumor-suppressive function. The mutated NF II gene is presumed to result in either a failure to synthesize Merlin or the production of a defective peptide that lacks the normal tumor-suppressive effect.

GENETIC PATHOGENESIS



CRITERIA FOR DIAGNOSIS OF NEUROFIBROMATOSIS

SOURCE- *Neurofibromatosis, conference statement. National Institutes of Health Consensus Development Conference*



Neurofibromatosis 1 :

Presence of two or more of the following-

- Six or more café-au-lait macules whose greatest diameter >5mm in pre-pubertal age and >15mm in postpubertal patients.
- Two or more neurofibromas of any type or one plexiform neurofibroma.
- Freckling in the axillary or inguinal region.
- Optic glioma
- Two or more Lisch nodules (iris).
- Sphenoid dysplasia, thinning of long bone cortex, with or without pseudo-arthritis.
- A parent, sibling or child with NF1 according to the above criteria.



NEUROFIBROMATOSIS TYPE 1

- BRAIN TUMORS- Glioma of optic pathway (esp pilocytic astrocytoma 15%), rarely acoustic neuroma & meningioma.
- OTHER CRANIAL ABNORMALITY- Hydrocephalus (tumor or aqueductal stenosis), idiopathic macrocephaly, cranial dysplasia (sphenoid wing aplasia, parieto-occipetal defect), speech impediments (50%), learning disability (25%), mental retardation (8.4%) & seizure (5%).
- SPINAL ANOMALY- Intra and extradural neurofibroma (MC), spinal meningocele, rarely spinal astrocytoma / meningioma, scalloping of vertebral body(10%), kyphoscoliosis, idiopathic vertebral dysplasia including atlanto-axial dislocation.



LAB. EVALUATION FOR NF1

- Protein truncation assay (PTA), which identifies a proportion of individuals with NF1, has been developed. Complete gene sequencing can be done . The detection rate using PTA varies from 65-70% in those who clearly have NF1 by clinical criteria. For patients with a single clinical finding, such as multiple café-au-lait spots in the absence of a positive family history, PTA (when positive) can be helpful.
- Sequencing of the neurofibromin gene has detection rate of 95%.
- Prenatal period- In a family with multiple affected members, linkage analysis can track the NF1 gene through the generations to determine which chromosome 17 region the fetus received.
- Identification of the mutation in the affected parent would permit prenatal diagnosis via amniocentesis or chorionic villus sample (CVS).



IMAGING EVALUATION IN NF 1

- Plain X ray - modeling defects, bony erosion, scoliosis.
- MRI head- preferred diagnostic modality. Unidentified bright spots (UBO) seen on T2-weighted images generally do not enhance, represent benign hamartomas. Rarely, hydrocephalus / Chiari type 1 malformation/brain tumors are seen.
- MRI is also useful in evaluating mediastinal masses, spinal cord tumors, deep plexiform neurofibromas, neurofibromas of the brachial or sacral plexus, as well as abdominopelvic lesions.
- PET- F-18 fluorodeoxyglucose (FDG) positron emission tomography (PET) may be used to stage and follow up MPNST.



OTHER EVALUATION METHOD IN NF 1

- EEG - Seizures are reported more often in patients with NF1 than in the general population (4-7%).
- Slit-lamp examination - who have only a single clinical criterion such as multiple café-au-lait spots.

CRITERIA FOR DIAGNOSIS OF NEUROFIBROMATOSIS

SOURCE- *Neurofibromatosis, conference statement. National Institutes of Health Consensus Development Conference*

Neurofibromatosis 2:

Presence of one of the following-

- Bilateral 8th nerve masses.
- A parent, sibling or child with NF2 and either unilateral 8th nerve masses
- Or any two of the following- neurofibroma, meningioma, glioma, Schwannoma, juvenile posterior subcapsular lenticular opacity.



NEUROFIBROMATOSIS TYPE 2

- INTRACRANIAL TUMORS- Bilateral acoustic schwannomas, meningioma.
- INTRASPINAL TUMORS- neurofibroma (aka *dumbbell tumor*), meningioma, ependymoma, low grade astrocytoma.



EVALUATION IN NF 2

- Detection rates for molecular-based testing approaches 65%.
- For families in which no mutation can be identified in a known affected individual, linkage analysis or indirect genetic testing methods may be utilized.
- For a parent who has NF2, prenatal testing can be done on amniocytes or chorionic villi.



EVALUATION IN NF 2

- **Radiography**- Plain films of the spine may be helpful in evaluating scoliosis.
- **MRI**- Mainstay for diagnosis and screening of CNS and spinal cord tumors. At risk individuals may be monitored for CNS tumors beginning in their teens, with annual MRIs of the head.
- **Other Tests**- Hearing evaluations including brainstem auditory-evoked response (BAER). Auditory screening on an annual basis may be quite useful in asymptomatic or pre-symptomatic individuals.
- **Dilated eye examinations**- To r/o significant cataracts.

MANAGEMENT ISSUES

NEUROFIBROMATOSIS TYPE 1



Medical Care

- For individuals diagnosed with NF1 – Annual eye examinations are important in early detection of optic nerve lesions. Cutaneous examination performed at each visit should look for new neurofibromas or progression of preexisting lesions. Skeletal involvement, including scoliosis, hemihypertrophy, or long-bone modeling defects.
- Blood pressure should be checked at each visit and hypertension treated promptly if detected. Hypertension workup should include evaluation for pheochromocytoma (ie, measurement of urinary catecholamines and metanephrines) and testing for renal artery stenosis. Percutaneous transluminal renal artery angioplasty may be effective to treat renal artery stenosis secondary to fibromuscular dysplasia.



MANAGEMENT ISSUES

NEUROFIBROMATOSIS TYPE 1

- **UBO/ Hamartomas are to be observed for any rapid change in size or any contrast enhancement which is suggestive of malignancy.**
- **LASER technology have permitted removal of small cutaneous neurofibromas .**
- **LASER treatment has not yet proven successful in permanent removal of café-au-lait spots.**



MANAGEMENT ISSUES

NEUROFIBROMATOSIS TYPE 1

Surgical Care

- **Surgical resection of neurofibromas . Neurofibromas that press on vital structures, > 5cm or grow rapidly deserve immediate attention.**
- **Patients with optic nerve glioma with compromised vision is to be excised, and for patients with preserved vision GKS can be tried. Chiasmatic glioma are managed conservatively with tumor biopsy and shunt operation for hydrocephalus.**
- **Plexiform neurofibromas may be difficult to approach surgically, often recurring after resection.**
- **Resection of spinal cord tumors is often necessary to prevent progressive paraplegia or quadriplegia.**
- **Orthopedic intervention is indicated for rapidly progressive scoliosis and for some severe bony defects.**
- **Some hypertensive patients with renal artery stenosis require surgical resection and repair instead of or following angioplasty.**



MANAGEMENT ISSUES

NEUROFIBROMATOSIS TYPE 2

Medical Care

- **Multidisciplinary clinic are important in respect to rapid advances in surgical management viz stereotactic radiosurgery and auditory brainstem implants.**
- **Individual with chances of having NF2, annual focused examinations, annual head MRIs and hearing evaluations with BAERs, seem to be reasonable screening options.**



MANAGEMENT ISSUES

NEUROFIBROMATOSIS TYPE 2

Surgical Care

- **Management depends on tumor size (>3/<3), mass effect in brain stem, hearing status. Patients with tumor size > 3 cm, presence of hearing loss & mass effect mandate surgical intervention. GKS is usually preferred for tumor < 3 cm with preserved hearing.**
- **Auditory brainstem implants (ABIs) have been used successfully in some patients with hearing loss secondary to vestibular schwannomas.**
- **Meningioma- surgical resection should be considered only when such lesions are causing serious, disabling symptoms.**
- **Resection of spinal cord tumors has its risks and benefits including a palliative function.**
- **Surgical resection of cutaneous or subcutaneous growths can be accomplished by plastic surgical consultation is advisable for areas of great cosmetic concern, such as the face.**



MANAGEMENT ISSUES FOLLOW UP

NEUROFIBROMATOSIS 1:

- **Annual assessment of the skin for typical lesions, BP, Neurological evaluation should include a careful history for headaches or motor or sensory symptoms.**
- **Annual ophthalmologic examinations should check for optic nerve pallor, visual acuity changes, visual field defects, and Lisch nodules.**



MANAGEMENT ISSUES FOLLOW UP

NEUROFIBROMATOSIS 2 :

- **Annual neurological examination looking for subtle deficits or changes in neurologic status that might suggest disease progression.**
- **Annual hearing screening with BAER with referral to an audiologist for amplification, augmentation, or speech therapy recommendations.**
- **Annual MRI to monitor existing lesions or look for presymptomatic lesions.**
- **Annual ophthalmologic evaluations to monitor visual acuity.**



MANAGEMENT ISSUES PROGNOSIS

- NF 1: Most individuals with NF1 lead relatively normal life. The major cause of increased morbidity and subsequent mortality are hypertension, sequelae of spinal cord lesions, and malignancy. Optic gliomas are indolent, low-grade lesions and in fact, Optic nerve lesions associated with NF1 are less aggressive. Occasionally, a large or deep plexiform neurofibroma residing within the brachial or pelvic plexus undergoes malignant transformation to a neurofibrosarcoma.
- NF 2: The prognosis of NF2 depends on age of onset of symptoms, degree of hearing deficit, number and location of tumors. The tumors themselves are relatively indolent and do not undergo malignant transformation. Vestibular schwannomas and meningiomas in NF2 tend to be more aggressive than in cases of sporadic tumors, with a tendency for more extensive local invasion and histologic evidence of increased mitoses.




MANAGEMENT ISSUES

MEDICAL/ LEGAL PITFALLS

- **Failure to identify at early stage –scoliosis, spinal cord lesions, CNS tumors so that interventions can be initiated prior to permanent neurological damage.**
- **Failure to identify and appropriately treat alternative causes of hypertension**
- **Failure to provide appropriate counseling / screening in high risk group.**

TUBEROUS SCLEROSIS COMPLEX (Bourneville's Disease)

- 
-
- Characterized by development of hamartomas in multiple organs.
 - TSC first described by von Recklinghausen (1862); Bourneville (1880) completely elaborated it and coined the term “tuberous sclerosis” .
 - Tuberous sclerosis is a genetic disorder with an autosomal dominant pattern of inheritance, and penetrance is 100%. TSC is caused by mutations on either of two genes TSC1 & TSC2, which encode for the proteins hamartin and tuberin respectively. These proteins act as tumour growth suppressors .
 - Vogt's triad- seizure, mental retardation and adenoma sebaceum(30%)

TUBEROUS SCLEROSIS COMPLEX

Diagnostic Criteria Committee of the National Tuberosclerosis Association (USA)

Major features

- **Facial angiofibromas or forehead plaque**
- **Nontraumatic unguual or periungual fibroma**
- **Hypomelanotic macules (>3)**
- **Shagreen patch (connective tissue nevus)**
- **Multiple retinal nodular hamartoma**
- **Cortical tuber.**
- **Subependymal giant cell astrocytoma**
- **Cardiac rhabdomyoma, single or multiple**
- **Lymphangiomyomatosis .**
- **Renal AML**



TUBEROUS SCLEROSIS COMPLEX

- **Minor features**
 - **Multiple randomly distributed pits in dental enamel**
 - **Hamartomatous rectal polyps.**
 - **Bone cysts.**
 - **Cerebral white matter radial migration lines.**
 - **Retinal achromic patch**
 - **"Confetti" skin lesions**
 - **Multiple renal cysts**
- **Diagnostic criteria**
 - **Definite TSC - Either two major features or one major feature plus two minor features**
 - **Probable TSC - One major plus one minor feature**
 - **Possible TSC - Either one major feature or two or more minor features**



TUBEROUS SCLEROSIS COMPLEX DIAGNOSIS

- **Molecular genetic testing : Genetic testing identifies mutations in up to 75-80% of affected individuals.**
- **Three diagnostic imaging procedures are usually undertaken: CT/ MRI scans of the brain, renal ultrasounds, and echocardiogram.**
- **CT or MRI scans of the brain- SEGA, hydrocephalus, cortical tubers. FLAIR is superior for identification of tubers. Contrast can be administered; however, both SEGAs and SENs typically enhance.**
- **EEG should be performed in patients with TSC in whom seizures are suspected**



TUBEROUS SCLEROSIS COMPLEX MANAGEMENT

Medical Care

- **Rapamycin (sirolimus) is a immunosuppressant, which forms an inhibitory complex with the immunophilin FKBP12, may have benefit in SEGA & AML.**
- **Antiepileptic medications (AEDs) are the mainstay of therapy for patients with TSC. Vigabatrin is the drug of first choice for children with TSC and infantile spasms. Topiramate, lamotrigine, valproate, and adrenocorticotrophic hormone (ACTH)/steroids are also useful. Carbamazepine, oxcarbazepine, and phenytoin may cause exacerbation of seizures, particularly in younger children and infants.**
- **Goals of treatment for patients with TSC are the same as for all patients with a multisystem chronic disease - providing the best possible quality of life with the fewest complications from the underlying disease process.**



TUBEROUS SCLEROSIS COMPLEX MANAGEMENT

Surgical Care

- **SEGA require resection if they produce hydrocephalus or significant mass effect. If a gross total resection can be achieved, recurrence is unlikely.**
- **Focal cortical resection: In most patients with TSC, resection of a cortical tuber is considered palliative rather than curative.**
- **Corpus callosotomy: May be effective in reducing atonic and tonic seizures (ie, drop attacks).**
- **Vagus nerve stimulation: At least a 50% reduction in seizure frequency.**



Von Hippel-Lindau (VHL) disease

(Retino Cerebellar Angiomas)

- **VHL is a rare inherited genetic condition involving the abnormal growth of tumors in parts of the body which are particularly rich in blood supply.**
- **Genetics- The VHL gene resides on the short arm of chromosome 3. The VHL gene may act as a classic tumor suppressor gene. As originally described by Knudson in his 2-hit theory of carcinogenesis, when an individual inherits a germline mutation that renders one VHL allele inactive, an acquired "second hit" in the other VHL allele in a somatic cell leaves that cell without tumor suppressor activity, leading to a selective growth advantage and an increased risk of malignant progression.**



V.H.L. DISEASE

- Types-

- Type 1 (angiomatosis without pheochromocytoma)

- Type 2 (angiomatosis with pheochromocytoma)

- Type 2A (low risk of renal cell carcinoma)

- Type 2B (high risk of renal cell carcinoma)

- Type 2C (only pheochromocytoma and no angiomatosis or RCC)

- **Retinal hemangioblastomas** (33%)- On ophthalmoscopy, appear as a dilated artery leading from the disc to a peripheral tumor with an engorged vein. Patients are usually asymptomatic, enlargement or a central location can result in significant visual loss. May predispose patients to retinal detachment, macular edema, and glaucoma.
- **CNS hemangioblastomas** - Histologically identical to retinal hemangioblastomas and are almost exclusively infratentorial. The mean age at diagnosis is 25 years. CNS hemangioblastomas are located in the cerebellum, brainstem and spinal cord. They are histologically benign. Hemorrhage into the lesions appears to be relatively unusual.



V.H.L. DISEASE

- **Renal involvement-** 76% of VHL patients demonstrate multiple renal cysts & have a significant predilection to degenerate to clear cell RCC, is the major cause of mortality. RCC is the presenting feature in only 10% of patients, but the risk of developing RCC by age 60 years is approximately 70%. Hemangiomas and benign adenomas of the kidney are also found.
- **Pheochromocytoma-** The risk of developing such tumors appears to hinge on the precise nature of the mutation responsible, type 1=10%, type 2= 50%.
- Various **other** lesions are observed, including epididymal cysts, epididymal cystadenomas, and multiple pancreatic cysts. Most pancreatic lesions are asymptomatic and benign, but, occasionally, a malignant islet cell tumor, a functioning islet cell tumor, or a frank pancreatic carcinoma arises in patients with VHL.
- **Endolymphatic sac** tumors have been described as part of the VHL spectrum. Searching for these tumors in at-risk individuals who present with otologic symptoms such as deafness and tinnitus is important.



V.H.L. DISEASE

Medical Care

- An annual physical examination, with specific attention to possible neurologic manifestations of CNS hemangioblastoma, is suggested.
- MRI is the preferred modality because of the preponderance of subtentorial and posterior fossa tumors.
- Medical care for patients with VHL is dictated entirely by the specific complications that present.
- A substantial minority of patients eventually require renal dialysis.
- Annual ophthalmologic examination is recommended because of the risk for retinal hemangioblastomas.



V.H.L. DISEASE

Surgical Care

- CNS hemangioblastomas are typically not malignant; thus, they can be monitored if their size is stable and they are not producing neurologic symptoms or signs. However, if these tumors cause neurologic symptoms, excision is required, GKS may have role.
- RCC- Partial nephrectomy or radiofrequency ablation is preferred to spare renal function if tumor involvement is not extensive. However, total nephrectomy is often necessary because of extensive tumor involvement. Since multiple primary tumors are common in VHL, bilateral nephrectomies may ultimately be required, necessitating renal dialysis or transplantation.
- Retinal hemangioblastomas should be monitored by an ophthalmologist. Treatment typically consists of laser treatment or cryotherapy to preserve vision.



ATAXIA-TELANGIECTASIA (LOUIS BAR DISEASE)

- Ataxia-telangiectasia (A-T) is an autosomal recessive, complex, multisystem disorder characterized by progressive neurologic impairment, cerebellar ataxia, variable immunodeficiency with susceptibility to sinopulmonary infections, impaired organ maturation, x-ray hypersensitivity, ocular and cutaneous telangiectasia, and a predisposition to malignancy.
- The disease is heterogeneous, both clinically and genetically, as shown by the existence of 4 complementation groups (A, C, D, E). The responsible gene (*ATM* gene) has been mapped to band 11q22-23.
- Incidence is about 1 case in 100,000 births.
- Death typically occurs in early or middle adolescence, usually from bronchopulmonary infection, less frequently from malignancy.



ATAXIA-TELANGIECTASIA

- The main abnormalities are ocular and cutaneous telangiectasia and neurologic symptoms (mainly ataxia and abnormal eye movements present in virtually all cases) and choreoathetosis (30-90% of patients).
- Laboratory markers- elevated levels of AFP and CEA. Chromosomal abnormalities, especially inversions and translocations involving chromosomes 7 and 14.
- Increased chromosomal breakage after exposure of cell cultures to ionizing radiation is a diagnostic importance.
- Protein-truncation testing of the entire ATM complementary DNA (cDNA) reveals as much as 66% of truncating mutations in the group with mutant alleles.




ATAXIA-TELANGIECTASIA

- MRI and sporadically made CT scan often show evidence of nonspecific cerebellar atrophy with widened cerebellar sulci and enlargement of the fourth ventricle.
- Radiologic findings of decreased or absent adenoidal tissue in the nasopharynx on lateral skull radiographs are so typical in A-T that they are of value in confirming the diagnosis.
- Chest radiographs may show a small or absent thymic shadow, decreased mediastinal lymphoid tissue, and pulmonary changes similar to those seen in cystic fibrosis.
- Hypoplastic peripheral lymphoid tissue is such a consistent clinical finding in A-T that the appearance of lymphadenopathy or even easily palpable lymph nodes has been highly suggestive of lymphoma.



ATAXIA-TELANGIECTASIA

- Although no specific treatment is available.
- Prevention of infections by regular injection of immunoglobulins is considered useful. Fetal thymus implants and stimulants of the immunologic system have given inconclusive results.
- Treatment of neurologic manifestations is disappointing. Beta-adrenergic blockers may improve fine motor coordination in some cases.
- Regular surveillance of heterozygotes for cancer should be part of family management. *ATM* heterozygosity was reported to be a risk factor for breast and lung cancers (Olsen, 2001; Swift, 1991; Swift, 1987). *ATM* carriers are also suggested to be more vulnerable at X-radiation, as in many cases breast cancer occurrence was preceded by x-ray exposure (Swift, 1987).
- Recently, desferrioxamine was shown to increase genomic stability of A-T cells (Shackelford, 2003) and, therefore, may present a promising tool in A-T treatment.
- Rehabilitation care.



STURGE WEBER SYNDROME (Encephalotrigeminal Angiomatosis)

- It consists of congenital hamartomatous malformations that may affect the eye, skin, and central nervous system at different times. Typically cutaneous angioma occur in the ophthalmic (V1) and maxillary (V2) distributions of the trigeminal nerve.
- SWS is referred to as complete when both CNS and facial angiomas are present and incomplete when only 1 area is affected without the other. The **Roach Scale** is used for classification, as follows:
 - Type I - Both facial & leptomenigeal angiomas(LA); may have glaucoma
 - Type II - Facial angioma alone (no CNS involvement); may have glaucoma
 - Type III - Isolated LA; usually no glaucoma



STURGE WEBER SYNDROME

- Embryonal developmental anomaly resulting from errors in mesodermal and ectodermal development. Unlike other neurocutaneous disorders (phakomatoses), SWS does not have a hereditary tendency.
- Fibronectin is a molecule that regulate angiogenesis, maintain the blood-brain barrier, blood vessel structure & function, as well as brain tissue responses to seizures. Comi et al reported that, in patients with SWS, decreased expression of fibronectin was noted in the leptomeningeal blood vessels while increased expression was noted in the parenchymal vessels. The leptomeningeal blood vessel circumference was decreased, while blood vessel density was increased in SWS.



STURGE WEBER SYNDROME

- Clinically present with seizures (72-93%), facial port wine stain (8%), hemiparesis, hemianopia, headache, developmental delay, buphthalmos.
- CSF analysis- Elevated protein
- Skull x-ray-Tram-track calcifications
- Angiography-Lack of superficial cortical veins, Nonfilling dural sinuses
- CT scan- Calcifications, tram-track calcifications, Cortical atrophy, Enlarged choroid plexus.
- MRI- Gadolinium enhancement of LA, Enlarged choroid plexus, Sinovenous occlusion, Cortical atrophy ,Accelerated myelination.
- SPECT- Hyperperfusion (early), Hypoperfusion(late).
- PET- Hypometabolism
- EEG- Reduced background activity, Polymorphic delta activity, Epileptiform features.



STURGE WEBER SYNDROME

Medical Care

- Anticonvulsants for seizure control, symptomatic and prophylactic therapy for headache, glaucoma treatment to reduce the IOP, and LASER therapy for PWS.
- Stroke-like events: Aspirin has been used for headaches and to prevent vascular disease, although it typically is used in patients who have had neurological progression or recurrent vascular events.

Surgical Care

- Surgery is desirable for refractory seizures, glaucoma, and specific problems related to various associated disorders, such as scoliosis.



FABRY' S DISEASE

- Fabry disease is an X-linked lysosomal storage disease that is caused by deficient activity of lysosomal enzyme α -galactosidase.
- The first clinical manifestations of the disease consists of episodes of severe pain in the extremities (acroparesthesias), hypohidrosis, corneal and lenticular changes, and skin lesions (angiokeratoma), develop in childhood.
- Renal failure, cardiovascular disease, and stroke are the major causes of morbidity and mortality, occurring in the fourth or fifth decade of life.
- α -galactosidase activity may be measured in plasma, serum, and leukocytes. Tissue biopsies and cultured skin fibroblasts may also be used to measure α -Gal A activity.
- DNA isolated from blood or biopsy specimens can be used for analysis of the α -Gal A gene sequence to identify the disease-causing mutation
- Renal evaluation – RFT, Renal biopsy.



FABRY' S DISEASE

- CNS evaluation-MRI is used to document evidence of brain ischemic disease. MRA may be indicated to assess cerebral vasculopathy. Peripheral nerves should be periodically assessed using a detailed neurological examination.
- Cardiac evaluation-Ventricular hypertrophy and septal thickening demonstrated echocardiography.
- **Treatment** - targeted the symptomatic effects. However, it is currently being treated at the cellular level through enzyme replacement therapy using Agalsidase alpha (Replagal) & Fabrazyme. Enzyme replacement therapy is not a cure, and must be infused recurrently for maximum benefit. Phenytoin and carbamazepin usually given for painful polyneuropathy. ERD may require kidney transplant.



OSLER WEBER RANDAU DISEASE

- Genetically determined disorder that affects blood vessels throughout the body and results in a tendency for bleeding. Autosomal dominant disorder characterized by vascular dysplasia and hemorrhage.
- The pathogenesis regarding the heterogeneity of vascular malformations is obscure. A partial explanation of the pathogenesis is with the identification of 2 distinct genes- the endoglin gene and the activin receptorlike kinase type I (ALK-1) gene.
- Recurrent epistaxis is the first symptom in 95% of patients. Patients usually have a family history of telangiectasia and recurrent bleeding in other family members.
- Risk of GI tract bleeding, Pulmonary AVMs may cause shunting to cause cyanosis, hypoxemia, and secondary polycythemia.
- Untreated patients have a 2% risk of stroke.



OSLER WEBER RANDAU DISEASE

- **Blood: Iron-deficiency anemia and thrombocytopenia are present**
- **Urine: To R/O hematuria.**
- **Stool: Evaluate the presence of blood in the stool.**
- **Chest radiography may show a peripheral noncalcified coin lesion attached by vascular strands to the hilus.**
- **CT scanning may be used to delineate AVMs of the lung or head.**
- **MRI helps to delineate the extent of pulmonary and CNS AVMs.**
- **Angiography is used when surgery is contemplated.**



OSLER WEBER RANDAU DISEASE

- **Individual skin lesions may be obliterated with cautery or LASER surgery.**
- **Recurrent epistaxis is treated surgically with nasal septum skin transplants by using skin , taken from the lower trunk.**
- **Severe cases may respond to estrogen therapy.**
- **Pulmonary hemorrhage may be controlled by using silicone balloon tamponade or other means.**



AIIMS EXPERIENCE

- Manish Singh Sharma et al in their retrospective study of 30 patients with NF 2 having 54 VS, who underwent GKS, analyzed the effect of GKS on tumor control and hearing preservation. Neurological deficit as 8th nerve involvement in 52/54, 7th nerve in 22/54, cerebellar signs in 15/54, 5th nerve involved in 14/54 and 9th 10th 11th involved in 5/54 nos. One patient with mild hearing loss (26-40 dB) and one with moderate hearing loss (41-55 dB) had deteriorated to severe hearing loss in post GKS period. Mean tumor size was 3.7 cc and marginal dose 12 Gy. They concluded that GKS for VS in NF2 patients provide satisfactory tumor control (87.5% at 27 months FU) and hearing preservation (66.7%).




CONCLUSION

- **Neurofibromatosis 1 , 2 and other neurocutaneous syndromes are diseases with numerous sequelae of which the neurosurgeon must be aware.**
- **Many of the associated conditions require neurosurgical and other modes of intervention.**
- **Evaluations of multiple systems and multiple family members is best accomplished by a multidisciplinary group. Diagnosis and treatment should be designed for the affected patient and his family members in a way to avoid fragmentation of medical care.**
- **Genetic basis of understanding the disease processes giving the hope for these types of diseases to be cured by genetic therapy**



REFERENCES

1. Riccardi VM. Neurofibromatosis: Phenotype, natural history and pathogenesis. 2nd ed. Baltimore: Johns Hopkins University Press, 1992.
2. Marchuk DA, Sauline AM, Tavakkol R. et al. c DNA cloning of the type 1 neurofibromatosis gene: complete sequence of the NF1 gene product. Genomics, 1991.
3. John H. Sampson, Robert L. Martuza. Neurofibromatosis and other Phakomatoses. Neurosurgery, 2nd edition (vol 1): 673-685.
4. Kathryn north: Neurofibromatosis type 1 in childhood,1997: 1-6.
5. Riccardi VM. Neurofibromatosis: Phenotype, natural history & pathogenesis. 2nd ed. John Hopkins univ press.1992.
6. Beth A Pletcher, MD, Associate Professor, Co-Director of The Neurofibromatosis Center of New Jersey, Department of Pediatrics, University of Medicine and Dentistry of New Jersey. emedicine.
7. David Neal Franz, MD, Professor, Departments of Pediatrics and Neurology, University of Cincinnati College of Medicine; Director, Tuberous Sclerosis Clinic, Cincinnati Children's Hospital Medical Center. Emedicine.



THANK YOU